Hemipelvectomy: Outcome in 84 Dogs and 16 Cats. A Veterinary Society of Surgical Oncology Retrospective Study

Jonathan P. Bray[1], MVSc, CertSAS, MACVSc, MSc (ClinOnc), Diplomate ECVS, Deanna R. Worley[2], BS, DVM, Diplomate ACVS, Ralph A. Henderson[3], Diplomate ACVIM & ACVS, Sarah E. Boston[4], DVM, DVSc, Diplomate ACVS, Kyle G. Mathews[5], DVM, MS, Diplomate ACVS, Giorgio Romanelli[6], Diplomate ECVS, Nicholas J. Bacon[4], MA, VetMB, Diplomate ECVS & ACVS, Julius M. Liptak[7], BVSc, MVetClinStud, FACVSc, Diplomate ACVS & ECVS, and Tim J. Scase[8], Bsc BVM & S, PhD, Diplomate ACVP

[1] Veterinary Teaching Hospital, Massey University, Palmerston North, New Zealand ,[2] Flint Animal Cancer Center and Department of Clinical Sciences, Colorado State University, Fort Collins, CO ,[3] College of Veterinary Medicine, Auburn University, Auburn, AL ,[4] College of Veterinary Medicine, University of Florida, Gainesville, FL ,[5] Department of Clinical Sciences, College of Veterinary Medicine, North Carolina State University, Raleigh, NC ,[6] Clinica Veterinaria Nerviano, Nerviano, Italy ,[7] Alta Vista Hospital, Ottawa, ON, Canada and [8] Bridge Pathology Ltd, Bristol, United Kingdom

Corresponding Author
Jonathan Bray, MVSc, CertSAS, MACVSc, MSc, Diplomate ECVS, Veterinary Teaching Hospital, Massey University, Private Bag 11-222, Palmerston North, New Zealand
E-mail: j.p.bray@massey.ac.nz

Submitted July 2012
Accepted March 2013

DOI:10.1111/j.1532-950X.2013.12080.x

Objective: To report clinical findings, perioperative complications and long-term outcome in dogs and cats that had hemipelvectomy surgery for treatment of neoplasia.
Study Design: Multi-institutional retrospective case series.
Animals: Dogs (n = 84) and cats (16).
Methods: Medical records (January 2000 to December 2009) of dogs and cats that had hemipelvectomy at participating institutions were reviewed. Postoperative progress and current status of the patient at the time of the study was determined by either medical record review, or via telephone contact with the referring veterinarian or owner.
Results: Complications were infrequent and usually minor. Hemorrhage was the main intraoperative complication; 2 dogs required blood transfusion. One dog developed an incisional hernia. In dogs, hemangiosarcoma had the worst prognosis with a median survival time (MST) of 179 days. MST for chondrosarcoma (1232 days), osteosarcoma (533 days), and soft tissue sarcoma (373 days) were not statistically different. Median disease-free interval (DFI) for local recurrence of all tumor types was 257 days. Cats had 75% survival at 1 year, which was significantly longer than dogs.
Conclusions: Survival times for most tumor types can be good, but surgical margins should be carefully evaluated to ensure complete tumor removal. Adjuvant therapies may be advisable particularly for dogs to reduce rates of local recurrence or distant metastasis.

Hemipelvectomy has been described as "an extensive, aggressive surgery for the management of tumors or functional abnormalities (e.g., fracture malunion) involving the pelvis or associated soft tissues."[1] Variable amounts of the hemi-pelvis may be removed, with preservation of a proportion of ilium or ischium possible, depending on the location of the lesion. Typically, hemipelvectomy necessitates amputation of the ipsilateral hind-limb, although this is not an essential part of the procedure and is dictated by the actual tissue compartment that needs to be removed as part of the oncologic procedure.

Apart from isolated case reports,[2,3] there is currently only 1 case series (9 dogs, 2 cats) that describes outcome after hemipelvectomy.[1] A variety of tumor types were described with a 62% disease-free survival at 12 months; osteosarcoma of the pelvis was associated with a poorer survival outcome than other tumors of the pelvis. A description of this surgical procedure was published, although no additional clinical information was provided.[4]

Hemipelvectomy is being performed more commonly; however, a lack of prognostic information makes it difficult to provide reliable data to clients on expected survival rates after surgery for different tumor types, and the role for adjuvant therapy has generally been determined by extrapolation of information on tumor behavior at different anatomic sites. Anecdotal observations suggest that tolerance of the surgery was good, with intraoperative and postoperative outcomes similar to those experienced with amputation.[5]

To improve knowledge about hemipelvectomy, members of the Veterinary Society of Surgical Oncology (VSSO) performed a multi-institutional retrospective study. Our

purpose is to report clinical findings and outcome of a cohort of 100 dogs and cats that had hemi-pelvectomy surgery for neoplastic disease.

MATERIALS AND METHODS

Medical records (January 2000 to December 2009) for dogs and cats that had hemipelvectomy at participating institutions were reviewed. Patients were included if surgery was a tumor affecting the bones or soft tissues of the thigh or pelvis, adequate clinical notes were available for review, and outcome could be determined by telephone contact with the owner or referring veterinarian.

Data was retrieved from medical records by the contributing authors using a standardized data accrual form. Data collected included: signalment, clinical signs noted by the owner, duration of signs before hemipelvectomy, previous treatments, ancillary tests performed and findings, tumor size, intraoperative complications, duration of hospitalization, time taken to become ambulatory after surgery, histologic findings, and adjunctive therapy used (chemotherapy or radiotherapy). Complications that occurred during hospitalization were defined as major if they resulted in either death or required surgical revision, and minor complications were defined as events that resolved promptly with medical intervention. Postoperative progress and current status, which included development of local tumor recurrence or metastasis was determined by either file review, or by telephone contact with the referring veterinarian or owner. If local tumor recurrence and/or metastasis was reported, attempts were made to establish whether this had been confirmed by either imaging or histopathology. Disease-free interval (DFI) was defined as days from surgery to the diagnosis of either local recurrence or metastasis. Survival time (ST) was defined as days from surgery to death. Cases were censored from survival analysis if they were lost to follow-up, or if the cause of death was not considered related to the neoplastic condition.

Histologic descriptions of the tumor, including assessment of resection margins, were obtained from the original pathology reports. When tissue blocks were available, the histopathology was reviewed by a single pathologist (TS). Tumors were graded by established protocols for each tumor type.[6,7]

Because a surgical technique for hemipelvectomy had not been published during the course of this study, most surgeons had developed their own dissection approach based the limited descriptions available.[1] Therefore, the precise surgical technique and perioperative management was determined by the attending surgeon and local hospital protocols. Anesthesia management was typically performed as for a pelvic limb amputation with consideration for multi-modal preemptive analgesia.[8] A description of the technique, and considerations for perioperative management has since been reported,[4] as has a modified technique based on experienced gained from this study.[9] The modified technique enables improved compartmental excision of neoplasms.

Statistical Analysis

Analyses were performed with statistical software (SPSS Statistics v18.0.3, IBM, New York, NY). Deaths from tumor, local recurrence or metastasis were defined end points. The Kaplan–Meier method was used to compare ST and DFI according to age, sex, neuter status, clinical signs, duration of signs, tumor size, tumor type, histologic characteristics (i.e., differentiation, necrosis, mitotic score, grade), histologic assessment of margins, adjuvant treatment used, and the development of local or distant tumor recurrence. Time to local or distant tumor recurrence was calculated from the date of surgery until recurrence as identified by the veterinarian. $P < .05$ was considered significant.

Prognostic factors that on univariate analysis had a value of $P < .1$ were further used to evaluate their independence by use of the Cox's proportional hazards model. Backward selection methods were used to create a fixed effects model, retaining only those values that had a P-value of $< .05$.

RESULTS

Demographics

Dogs (n = 84) and 16 cats from 9 institutions met the inclusion criteria. Cases were accrued from the United States (Colorado State University, n = 32; Auburn University, 16; North Carolina State University, 8; University of Florida, 4), United Kingdom (Davies Veterinary Specialists, 17), Canada (Ontario Veterinary College, 10; Alta Vista Hospital, 4; Simcoe Veterinary Surgical Referrals, 1), and Italy (Clinica Veterinaria Nerviano, 8).

Of 84 dogs, 48 were female (73% spayed) and 36 male (63% castrated). Median age was 9 years (range, 2–15.7 years) at time of surgery. Affected dog breeds included Labrador retriever (n = 16), Rottweiler (9), Golden retriever (8), German shepherd (4), Staffordshire Bull terrier (3), Miniature schnauzer (3), Bernese mountain dog (2), and 1 each of various other breed types. Of 16 cats, 8 were female and 8 were male; all cats were neutered. Median age was 9 years (range, 4.2–16 years). All cats were domestic shorthaired.

Clinical Findings

Clinical signs that prompted referral for hemipelvectomy differed markedly between species. Dogs (47/84; 56%) presented with a pelvic limb lameness and a neoplastic process was ultimately identified. In 33 (39%) dogs, a palpable mass was evident. Three dogs presented because of fecal tenesmus and constipation and a mass causing intrapelvic obstruction was identified. By contrast, cats (13/16; 81%) commonly presented because of a mass affecting the pelvis or thigh; 3 cats were presented for lameness.

For dogs and cats, median duration of clinical signs before definitive surgery was 45 days (range, 1–862 days) with 85% having hemipelvectomy within 6 months of initial signs of disease. In 2 dogs and 2 cats, clinical signs were present for >1 year before surgical management.

Dogs with a mass presented for hemipelvectomy surgery sooner (median, 36 days) than dogs that were lame (median, 51 days), but this finding was not significant ($P = .12$). Four dogs with a palpable mass were not referred for >6 months after initial recognition of their mass, because the mass was not associated with pain or disability, and investigations were only considered when rapid growth of the mass was noted or there was deterioration in function. In 7 (21%) dogs, the referring veterinarian had performed mass excision, but incomplete margins were obtained in each dog. One had an infiltrative lipoma and repeated "debulking" had been performed over >2 years in an attempt to control tumor regrowth. One dog had been treated with intra-arterial chemotherapy in an attempt to avoid the need for surgery, but with continued progression of the mass the owners eventually consented to definitive surgical resection.

Lame dogs were often treated with a variety of anti-inflammatory medications before surgery to manage the lameness. Once a mass had been identified, 24 (51%) lame dogs had incisional biopsy (13 open, 7 tru-cut) or fine-needle aspiration (4) to obtain a diagnosis. In 2, surgical resection of the mass (femoral neck tumors) had been attempted but incomplete margins were obtained.

Dogs with primary bone tumors tended to present with a more acute clinical history, with 24/26 (92%) and 7/9 (77%) respectively of osteosarcoma and chondrosarcoma cases presenting for surgery within 3 months of the onset of clinical signs. This contrasted with only 17/30 (57%) soft tissue sarcoma cases being presented for hemipelvectomy within the same time interval.

Cats tended to have a more protracted clinical course (median, 129 days; range, 2–442 days) than dogs before referral for hemipelvectomy. In contrast to dogs, cats that were lame were referred for surgery earlier (median, 57 days) than cats with an obvious mass (median, 134 days). Surgical resection of a mass was also more commonly attempted in cats (8/13) compared to dogs; incomplete margins were obtained in each instance. In 3 cats, there were repeated surgical attempts to remove the mass (up to 3 procedures in 2 cats) during the year before hemipelvectomy.

Diagnostic Findings

Precise tumor measurements were available in 37 dogs and 15 cats. In dogs, more than two-thirds of the tumors were longer than 5 cm along their widest axis (range, 2–20 cm; median, 8.6 cm) whereas in cats, median tumor size was 4 cm (range, 1–9 cm).

Hematologic and serum biochemical evaluations were performed before surgery in 91 patients and urinalysis in 31. Other than mild increases in alkaline phosphatase (ALKP; 167, 201, and 955 IU/L; reference interval, 18–141 IU/L]) in 3 dog with osteosarcoma, no consistent abnormalities were identified.

Clinical staging was performed in all animals, but the extent of investigation varied. Thoracic imaging was performed with radiography (79) or computed tomography (5); a suspected pulmonary metastatic nodule was identified in 1 case by radiography but no further investigation was performed. Thoracic imaging was refused by 1 owner. In the other 15 cases, thoracic imaging was performed by the referring veterinarian and no metastases were identified. Abdominal ultrasound, with fine needle aspiration of the sublumbar lymph nodes if they were considered abnormal, was performed in 21 patients. No evidence of gross metastatic disease to the abdomen was reported. Bone scans were performed in 18 patients and increased uptake at sites distant from the tumor was identified in 12 patients; in 8 cases, localization was periarticular and was consistent with degenerative joint disease. In 4 cases, increased uptake in the ribs (3) or mid-diaphysis of the radius (1) were investigated with radiography; these lesions were not considered associated with metastatic disease. Coaxial imaging of the pelvis was performed in 65 patients (59 CT, 6 MRI) that provided detailed information on the location and extent of the tumor.

Neoadjuvant treatment was performed in 1 dog with 4×8 Gy weekly treatment with radiotherapy and Lomustine. The original intent for this treatment was palliation, but surgery was reconsidered because of a poor response and tumor progression.

Perioperative Outcome

No intraoperative complications were reported in 92 patients. Substantial intraoperative hemorrhage occurred in 7 patients and blood transfusions were performed in 2. Iatrogenic laceration of the urethra occurred in 1 dog during total hemipelvectomy for an osteosarcoma with a large intra-pelvic component; the urethral injury was repaired immediately and no subsequent complications were observed.

No postoperative complications were reported in 84 patients. Major complications developed in 1 dog and included an incisional hernia and scrotal swelling which was managed by scrotal ablation and repair of the dehisced abdominal wall. Minor complications were reported in 11 patients and included wound complications (swelling, 2; discharge, 1; dehiscence, 1), corneal ulceration (2) and aspiration pneumonia (1). Urinary retention, suspected to be because of the use of epidural analgesia, was the most commonly reported complication occurring in 4 dogs. Bladder care, with intermittent urinary catheterization resulted in normal urination within 1–2 days. None of the complications reported were life-threatening and all quickly resolved with appropriate nursing care.

Median hospitalization was 3 days; 90% of patients were discharged within 7 days. Drain management was the predominant reason for longer hospitalization. All animals were ambulatory within 24 hours of surgery, although 4 were supported with a sling for 24–48 hours after surgery.

Long-term function was reported by 94 owners to be excellent and consistent with that expected for a pelvic limb amputee; however, 2 owners reported their dogs failed to adjust well to their amputee status and had limited mobility. One dog was a Golden retriever and the other was a mixed breed dog; from the clinical notes available there appeared little

explanation for their poor adaptation after amputation. Both dogs were euthanatized, at owner request, 90 and 52 days (respectively) after surgery. Another 4 dogs had good initial function after surgery, but were later euthanatized because of orthopedic disease (e.g., cruciate instability (2), coxofemoral luxation, and coxofemoral DJD) in the contralateral limb.

Histologic Examination

In dogs, tumor types (Table 1) included soft tissue sarcoma (n = 33; fibrosarcoma, spindle cell sarcoma, liposarcoma, myxosarcoma, histiocytic sarcoma, and peripheral nerve sheath tumors), osteosarcoma (28), chondrosarcoma (9), hemangiosarcoma (6) and infiltrative lipoma (5). Other tumor types included a mast cell tumor (1) and multilobular osteochondrosarcoma (1). In 1 dog, no tumor could be identified in the submitted tissue despite pre-operative investigations supporting the presence of a neoplastic disorder. This dog had an acute 10/10 lameness of 2 months duration. Radiographs revealed a severely destructive and moderately osteoproliferative process affecting the left coxofemoral joint, with areas of lysis within the femoral neck. Preoperative cytology was suggestive of a neoplastic process, but on histologic assessment of the submitted limb, a diagnosis of severe degenerative joint disease was made.

Histologic review was performed in 46 cases. Of 9 chondrosarcoma, 8 were considered intermediate grade.[10] For osteosarcoma, 2 were classified as high grade, 5 as intermediate, and 1 as low grade.[7] For soft tissue sarcoma, 14 were intermediate grade and 10 were low grade.[11]

In cats, all tumors were mesenchymal in origin; soft tissue sarcoma (all fibrosarcoma, 11), osteosarcoma (3) and chondrosarcoma (2). Histologic characteristics of the fibrosarcoma were consistent with injection site sarcoma, with aggregations of lymphoid inflammatory cells, areas of necrosis, high numbers of mitotic figures and extensive cellular pleomorphism.[12]

In the 63 cases where cytologic or histologic evidence of neoplasia was obtained before surgery, the final histologic diagnosis differed from preoperative interpretation in 20 cases. In 11 cases, the biopsy provided a diagnosis of "sarcoma" or "neoplasia" but was unable to provide more specific tissue differentiation. In the other 9 cases, the final diagnosis changed from 1 classification of sarcoma to another (e.g., chondrosarcoma to osteosarcoma, or fibrosarcoma to chondrosarcoma).

Clean resection margins were not always obtained despite the extent of surgery, and resections were considered incomplete in 29 dogs and 4 cats (Table 2); however, margin assessment proved insensitive to determine tumor recurrence. Local tumor recurrence occurred 8 (16%) dogs despite clean histologic margins; mean DFI was 302 days. Tumor recurrence had not developed in 4 (25%) dogs alive at the time of the study despite incomplete resections being reported on histology; median follow-up was 337 days. There was no statistical difference between dogs or cats for ability to achieve a clean margin.

Outcome

Canine Tumors. Median follow-up was 296 days (range, 5–2703 days). From Kaplan–Meier analysis, median ST was 533 days (95% CI: 289, 776; Fig 1). There were no differences in outcome between institutions. ST for tumor types in dog are outlined in Table 3. None of the dogs with infiltrative lipoma developed local tumor recurrence or metastatic disease; 1 dog was alive at study end (2703 days) with the other 3 dogs dying from unrelated disease.

Of the malignant tumor types, hemangiosarcoma had the worst prognosis with a median ST of 179 days (range, 0–440 days; Fig 2) When all other malignant mesenchymal tumors (i.e., osteosarcoma, chondrosarcoma, soft tissue sarcoma) were combined and compared with hemangiosarcoma, the hazard ratio for death was 2.4 but this was not statistically significant ($P = .075$; 95% CI: 0.92, 6.2; Fig 3) Five of 6 dogs with

Table 1 Locations for Tumor types in 83 Dogs and 16 Cats

			Bone Tumors				Soft Tissue Tumors	
Species	Tumor Type	N	Acetabulum Area	Ileum/ Iliosacral	Ischium/Pubis	Proximal Femur/ Femoral Neck	Pelvic Nerves	Thigh Muscles
Canine	Chondrosarcoma	9	1	3	1	2		2
	Hemangiosarcoma	6		1		1		4
	Infiltrative lipoma	5						5
	Osteosarcoma	28	2	6	1	19		
	Soft tissue sarcoma	33	2	2		5	5	19
	Multilobular osteochondrosarcoma	1		1				
	Mast cell tumor	1						1
	TOTAL (83)*		5	13	2	27	5	31
Feline	Chondrosarcoma	2						2
	Osteosarcoma	3		1	1			1
	Soft tissue sarcoma	11						11
	TOTAL (16)			1	1			14

*Note: In 1 dog, a coxofemoral mass was assessed to be non-neoplastic on final histologic examination.

Table 2 Rates of Local Recurrence, Metastasis, and Survival for Different Tumor Types in 83 Dogs and 16 Cats Based on Completeness of Tumor Resection

Species	Tumor Type	N	Clean Margins?		Local Recurrence		Metastasis		Death From Tumor	
					No	Yes	No	Yes	No	Yes
Canine	Chondrosarcoma	9	No	6	6	—	2	4	4	2
			Yes	3	2	1	2	1	2	1
	Hemangiosarcoma	6	No	2	2	—	—	2	—	2
			Yes	4	4	—	1	3	1	3
	Infiltrative lipoma	5	No	—	—	—	—	—	—	—
			Yes	5	5	—	4	1	4	1
	Mast cell tumor	1	No	1	—	1	1	—	—	1
			Yes	—	—	—	—	—	—	—
	Multilobular osteochondrosarcoma	1	No	1	1	—	1	—	1	—
			Yes	—	—	—	—	—	—	—
	Osteosarcoma	28	No	7	6	1	2	4	2	5
			Yes	21	17	4	11	7	11	10
	Soft tissue sarcoma	33	No	12	7	5	7	4	4	8
			Yes	20	17	3	11	8	11	9
Feline	Chondrosarcoma	2	No	1	—	1	1	—	—	1
			Yes	1	1	—	1	—	1	—
	Osteosarcoma	3	No	1	—	—	—	1	—	1
			Yes	2	2	—	2	—	2	—
	Soft tissue sarcoma	11	No	2	2	—	1	1	1	1
			Yes	9	8	1	8	—	8	1

hemangiosarcoma died because of metastatic disease; 4 had been administered adjuvant chemotherapy. There were insufficient patients in this group to demonstrate a statistical survival advantage for adjuvant therapy. When comparing chondrosarcoma, osteosarcoma and soft tissue sarcoma, no statistical difference in survival could be detected between tumor types. Tumor grade was not statistically associated with differences in outcome for each tumor type.

Median DFI for local recurrence for all tumor types was 257 days (95% CI: 166, 347 days). Rate of local recurrence and apparent metastatic potential is provided in Table 4. Forty-three dogs died or were euthanatized because of local recurrence (n = 11), distant metastatic disease (24) or both (8). One dog died at home from a suspected pulmonary thromboembolism 5 days after surgery, but no post-mortem was performed. Another dog was euthanatized 9 days after surgery at owner request after dehiscence of the wound. Four dogs were euthanatized because of development of orthopedic disease in the contralateral pelvic limb that severely limited their mobility; median ST was 362 days (range, 52–537 days). Disease status of 3 animals at death was unknown. Sixteen dogs were alive at study end; local recurrence or metastasis had been recently diagnosed in 4 of these dogs.

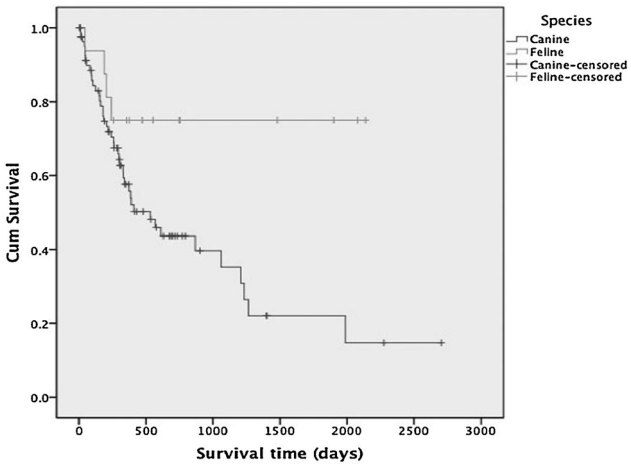

Figure 1 Kaplan–Meier survival curve after hemipelvectomy in the dog and cat (for all tumor types).

Development of local recurrence was associated with an increased rate of death ($\chi^2 = 13.5$, $P = .0002$) and reduced overall survival (HR 3.8; $P = .005$: 95% CI: 1.9, 7.2). There was no difference in either ST or DFI based on completeness of resection. When comparing chondrosarcoma, osteosarcoma, and soft tissue sarcoma, no statistical difference in local recurrence could be identified between tumor types.

Development of metastatic disease was common within the study population with metastatic lesions developing or being suspected in 37 (44%) dogs. Median DFI for metastasis for all tumor types was 248 days (95% CI: 130, 365 days). Metastatic disease was diagnosed based on imaging (26), cytology (4), histology (3) or necropsy (1). In the other 3 cases, metastatic disease was suspected based on development of clinical signs that included seizures (2) and abdominal effusion (1).

Adjuvant treatments were performed in 31 dogs; chemotherapy (26), radiotherapy (2), intralesional chemotherapy (1) and combined chemotherapy and radiation (2). Adjuvant chemotherapy was used after surgery for chondrosarcoma (1/9), osteosarcoma (16/28), soft tissue sarcoma (5/34), and hemangiosarcoma (4/6). Chemotherapy protocols differed between institutions and tumor type, and patients

Table 3 Survival Times by Individual Tumor Type in 83 Dogs

Tumor Type	N	Mean Survival Time (Days)	95% CI	Disease-Free Interval: Local Recurrence	Disease-Free Interval: Metastatic Disease	% Survival: 1 Year	% Survival: 2 Years
Mast cell tumor	1	25		25		0	0
Multilobular osteochondrosarcoma	1	715		—		100	100
Infiltrative lipoma	4	940		—		100	100
Chondrosarcoma	9	1232	640–1823	95	499	87	87
Hemangiosarcoma	6	179	0–440	—	117	33	0
Osteosarcoma	28	533	0–1090	49	126	51	35
Soft tissue sarcoma	34	373	247–498	226	261	47	38
Overall*	83	386	182–589			56	44

*Note: 1 dog was excluded from tabulation because the lesion was non-neoplastic.

received single agent doxorubicin (20–30 mg/m^2 every 3 weeks; n = 8), carboplatin (250 mg/m^2 every 3 weeks; n = 4), cisplatin (60 mg/m^2 every 3 weeks; n = 3), alternating cycles of carboplatin and doxorubicin (5) or alternating cycles of cisplatin and doxorubicin (n = 1). Type of chemotherapy administered was not reported in 5 dogs. Significantly improved median ST was evident for dogs with soft tissue sarcoma receiving chemotherapy (258 days vs. 409 days, $P = .03$), but chemotherapy did not significantly improve ST for patients with osteosarcoma or hemangiosarcoma.

On multivariate analysis, there were no factors of significance that were predictive of improved survival or DFI.

Feline Tumors. Median follow-up was 1042 days (range, 45–2138 days). Cats (Table 5) had a significantly longer ST compared with dogs (HR 0.3; $P = .03$; 95% CI: 0.11, 0.88; Fig 1) From Kaplan–Meier analysis, median ST was not reached with 75% survival at 1 year (mean ST for all tumor types was 1646 days).

When comparing chondrosarcoma, osteosarcoma, and soft tissue sarcoma, no statistical difference in survival was found between tumor types (Fig 4) Tumor grade was not statistically associated with differences in outcome across all tumor types. Clean resection margins were not consistently achieved for all tumor types (Table 2) but local recurrences were uncommon despite this finding. Clean resection margins were associated with statistically significant improved mean ST (1965 days vs. 198 days, $P = .003$). There were no differences in outcome between institutions.

Four cats died or were euthanatized because of local recurrence (n = 2), distant metastatic disease (n = 1) or both (n = 1). The disease status of 1 cat at death was unknown. Nine cats were alive and disease-free at study end. Rate of local recurrence and apparent metastatic potential is in Table 6. Median DFI for local recurrence for all tumor types was 105 days (95% CI: 9, 210 days). Metastatic disease was less common than in the dog, developing or being suspected in only 2 (12.5%) cats, both with osteosarcoma. The diagnosis of metastatic disease was determined based on thoracic imaging (1) or cytologic examination (1). One cat died acutely (ST, 188 days) because of respiratory difficulty, pleural effusion, and hemopericardium. Local tumor recurrence and pulmonary metastasis was diagnosed in another cat 105 days after surgery, which was euthanatized 3 months later (day 205).

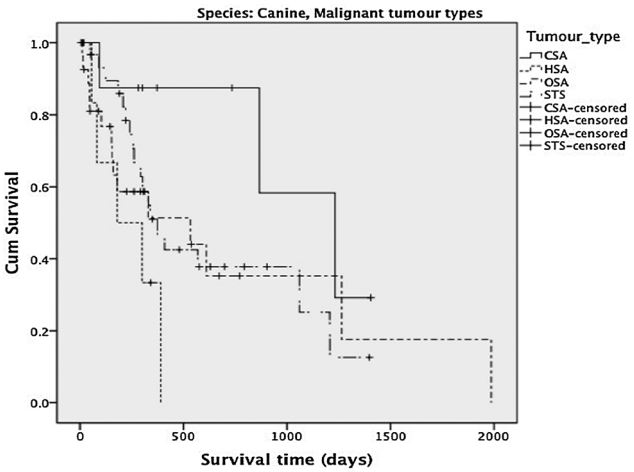

Figure 2 Kaplan–Meier survival curve after hemipelvectomy in dogs for malignant mesenchymal tumors.

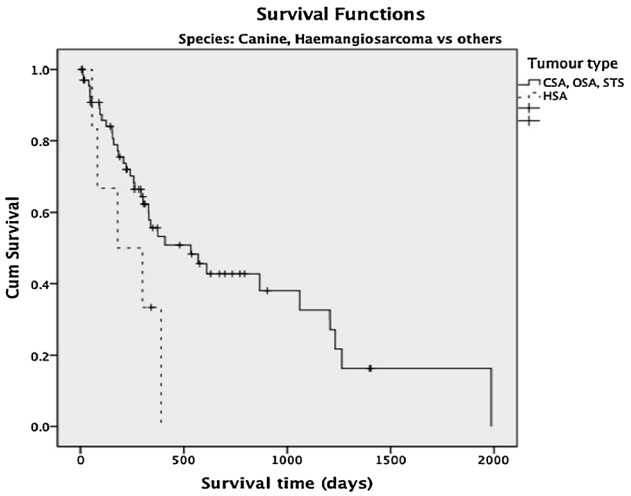

Figure 3 Kaplan–Meier survival curve after hemipelvectomy in dogs. Hemangiosarcoma versus all other malignant mesenchymal tumors.

Table 4 Rates of Local Recurrence and Apparent Metastatic Potential in 83 Canine Tumors

Tumor Type	N	Local Recurrence	Metastatic Disease	Local Recurrence and Metastatic Disease	No Known Recurrence	Lost to Follow-up
Mast cell tumor	1	1				
Multilobular Osteochondrosarcoma	1				1 (100%)	
Infiltrative lipoma	4				4 (100%)	
Chondrosarcoma	9	1 (11%)	5 (56%)		3 (33%)	
Hemangiosarcoma	6		5 (83%)		1 (17%)	
Osteosarcoma	28	6 (21%)	13 (46%)	1 (4%)	4 (14%)	4 (14%)
Soft tissue sarcoma	34	5 (15%)	9 (26%)	5 (15%)	8 (24%)	3 (9%)
Overall	83	13 (16%)	32 (39%)	6 (7%)	21 (25%)	7 (8%)

Adjuvant therapy was used after surgery for soft tissue sarcoma only (chemotherapy, 3 cats; combined chemotherapy and external beam radiation, 2 cats). There were insufficient cases treated with chemotherapy for statistical analyses.

On multivariate analysis, the only significant risk factor for an improved ST was clean histologic margins (HR 0.51; $P = .03$; 95% CI: 0.29, 0.93).

DISCUSSION

Our purpose was to report clinical findings and outcome for a cohort of 84 dogs and 16 cats that had hemipelvectomy for neoplastic disease. Our findings suggest that hemipelvectomy is an effective surgical procedure for radical excision of various tumor types arising from or near the pelvis. Perioperative complications were infrequent, with patient recovery and long-term function no different than described for conventional pelvic limb amputation.[5] We believe this report redresses the perception that hemipelvectomy is a "complex, aggressive surgical procedure with high morbidity"[1]; however, we agree with Kramer et al[4] that this surgical procedure requires careful planning, thorough familiarity with regional anatomy, meticulous adherence to techniques of surgical oncology, and good perioperative anesthesia, analgesia and nursing care.

In our study population, hemipelvectomy provided a curative solution for benign but extensive lesions such as infiltrative lipoma. These tumors often extended the length of the upper thigh and had infiltrated extensively into the thigh muscles (Fig 5 A,B). Other less extensive resection options were considered either impossible or had previously failed. Hemipelvectomy enabled complete anatomic resection of the affected tissue compartment in the pelvic limb ensuring curative resection.[13] Despite these successes, 43 (51%) dogs and 4 (25%) cats died as a consequence of local tumor recurrence or distant metastatic disease. In dogs, hemangiosarcoma had the poorest prognosis with a median ST of 179 days. For other mesenchymal tumors (chondrosarcoma, soft tissue sarcoma, osteosarcoma) no statistical difference in survival was apparent between tumor types. The similarity in outcome between tumor types is contrary to the published outcomes when these tumors are located elsewhere on the axial skeleton.[14–17] One explanation for this discrepancy may be the relatively small patient numbers in some tumor groups (e.g., chondrosarcoma). Nevertheless, based on our results, dogs with osteosarcoma of the upper thigh and pelvis may have a good outcome with a lower rate of metastatic disease and prolonged survival compared with osteosarcoma located in the appendicular skeleton. Some authors have suggested that osteosarcoma arising from flat or irregular bones (like the mandible, ribs or pelvis) may have different biologic behavior and prognosis to appendicular tumours,[18,19] but this has not been confirmed. Dickerson et al[16] also considered that the prevalence of metastasis and median ST for large-breed dogs with osteosarcoma of the axial skeleton was similar to that reported for large-breed dogs with appendicular skeleton

Table 5 Overall Survival Times for Individual Tumor Types in 16 Cats

Tumor type	N	Mean Survival Time	% survival 1 Year	% survival 2 Years
Chondrosarcoma	2	395	50%	50%
Osteosarcoma	3	431	66%	66%
Soft tissue sarcoma	11	1789	81%	81%
Overall	16	1645	75%	75%

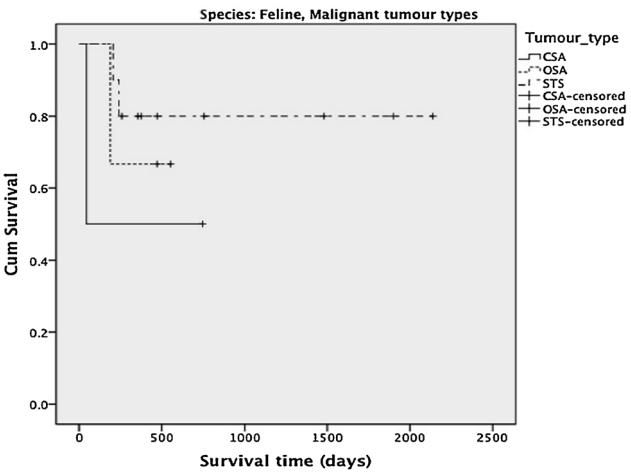

Figure 4 Kaplan–Meier survival curve after hemipelvectomy in cats for malignant mesenchymal tumors.

Table 6 Rates of Local Recurrence and Apparent Metastatic Potential in 16 Cats

Tumor Type	N	Local Recurrence	Metastatic Disease	Local Recurrence and Metastatic Disease	No known Recurrence	Lost to Follow-up
Chondrosarcoma	2	1 (50%)			1 (50%)	
Osteosarcoma (all variants)	3		1 (33%)		2 (67%)	
Soft tissue sarcoma	11	1 (9%)		1 (9%)	8 (73%)	1 (9%)
Overall	16	2 (12.5%)	1 (6.3%)	1 (6.3%)	11 (69%)	1 (6.3%)

osteosarcoma; however, complete surgical resection of the primary tumor was very rarely accomplished in that study. A recent report that evaluated prognosis for osteosarcoma of extracranial flat and irregular bones found a median ST of 12 weeks with a 1-year survival rate of 17.0%, similar to reports for appendicular osteosarcoma.[20] Meta-analysis of appendicular osteosarcoma showed that dogs with the primary tumor located in their (proximal) humerus had shorter STs than dogs with the primary tumor located elsewhere in their appendicular skeleton (HR 1.86; 95% CI: 1.34, 2.57), but proximal femoral tumors were not specifically evaluated as a subgroup in this study.

The predominance of apparent injection site sarcoma (FISS) in most cats in our study is of concern, and supports the findings of Shaw et al,[21] who reported a progressive decrease in tumors developing in the interscapular site but a corresponding increase at other sites (including the pelvis and lateral abdominal wall). These findings suggests that many veterinarians are failing to completely implement the guidelines published by the Vaccine Associated Feline Sarcoma Task Force (VAFSTF).[22] These recommendations were to administer rabies vaccine in the right pelvic limb as distally as possible, FeLV vaccine in the left pelvic limb as distally as possible, and the FVRCP $\pm$ C vaccine in the right shoulder. The intention for these guidelines was to ensure that any resultant tumor could be successfully managed by routine amputation.[22] Although most FISS in our study appear to have been successfully managed by hemipelvectomy, this surgery is considerably more complex than pelvic limb amputation. Local recurrence also remained a concern. We reiterate the conclusions of Shaw et al,[21] who stated that "the VAFSTF recommendations should be adhered to more strictly, with emphasis on placement of injections in limbs as distally as possible to prevent misadministration of injections with subsequent tumor formation at the lateral aspect of the abdomen and proximal thigh, where complete surgical excision is more invasive than amputation alone and may result in a higher morbidity rate."

The high rates of incomplete resection for many tumors in our report may reflect the large tumor size at the time of diagnosis, tumor location, and some anatomic limits to resection (e.g., sacrum and peripheral nerve sheath tumor affecting nerves of the lumbosacral plexus). Furthermore, because there has been limited information on hemipelvectomy, many of the surgeons contributing to this study had to develop their own surgical approach for the resection. Tumors at this location are often very large at the time of diagnosis.

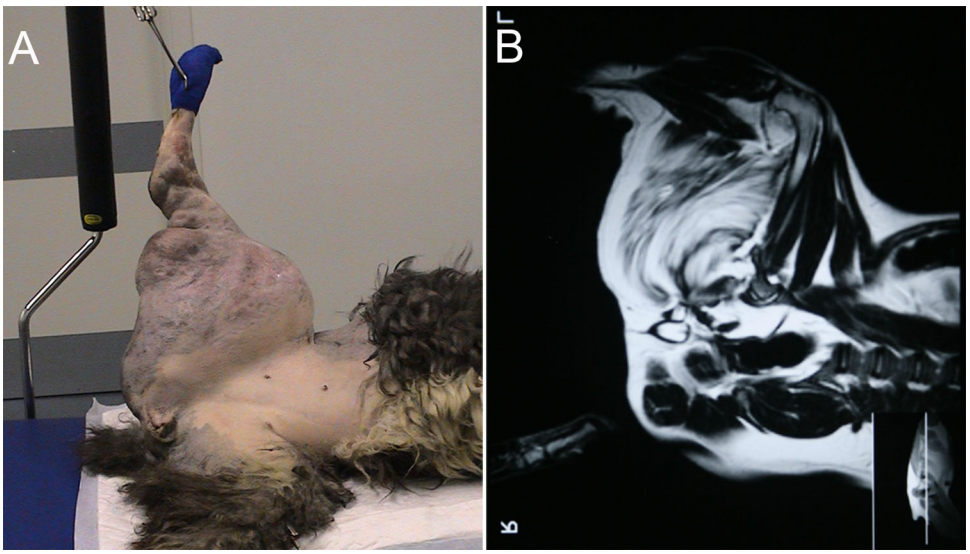

Figure 5 A: Extensive infiltrative lipoma affecting the pelvic limb of an 8 year Old English Sheepdog. Debulking surgeries had been performed on 3 occasions. B: MRI image of the affected limb reveals the extent of the infiltrated muscular tissue. The tumor has not extended into the cranial extensor muscle compartment or infiltrated into the contralateral adductor muscle allowing a compartmental resection of the tumor to be accomplished.

Some surgeons commented they considered their intervention a heroic attempt to manage large and difficult tumors that were causing considerable morbidity. It is likely that with improved experience and understanding of the limitations of hemipelvectomy, oncologic surgeons may be able to select and manage their patients more effectively. However, given the good tolerance of this surgery by patients, hemipelvectomy may remain an effective palliative option even if complete resection is not thought to be possible. Consideration should also be given to using radiotherapy to manage a planned (or unplanned) incomplete resection margin to improve local tumor control.[23–25]

It is worth noting that the accuracy of margin assessment was poor, with local tumor recurrence developing in 13 (20%) of dogs whose margins had been reported as clean, but no recurrence developing in 4 (12%) patients that had incomplete resections. This apparent inaccuracy may reflect the difficulties of selecting a representative section when the pathologist is presented with an extensive specimen as with hemipelvectomy, and gross evaluation of the resection margin is important. In a study that evaluated the accuracy of histologic margin evaluation after amputation, the authors concluded that when the neoplasm was greater than one joint from the excision margin or any suspected gross lesion was >2 cm from the excision margin histopathology along the margins did not reveal occult neoplastic cells (personal communication, Dr Donald Meuten, 2011) Accurate margin analysis requires good communication between the surgeon and pathologist.[26] Because the surgeon has the best ability to recognize areas of the resection that may have been compromised or in closest proximity to the gross tumor, the surgeon should ink the resection margins or tag suspicious areas with suture to improve the accuracy of margin assessment.[26]

Metastatic disease was a common reason for death in dogs that had hemipelvectomy (32/84); the metastatic rate for soft tissue sarcoma (40%) and chondrosarcoma (45%) was high and only a small proportion of these patients received adjuvant chemotherapy. This may reflect a bias by clinicians to recommend chemotherapy more commonly for tumors with a historical tendency for high metastatic potential (e.g., hemangiosarcoma, osteosarcoma). Chondrosarcoma are also not thought to respond well to chemotherapy.[27] The high rates of metastasis would suggest adjuvant therapy should be an important consideration for all patients undergoing hemipelvectomy for a malignant tumor. Whereas a significantly improved median ST was evident for dogs with soft tissue sarcoma receiving chemotherapy (258 days vs. 409 days, respectively, $P = .03$), only 5 patients received chemotherapy in our study so this finding should be interpreted with caution. The role of chemotherapy in soft tissue sarcoma is generally considered limited, with most human and veterinary studies failing to demonstrate a survival advantage.[23,24,27,28] It is generally recommended for higher grade tumors only,[23,24] and metronomic chemotherapy is considered to offer benefits over conventional chemotherapy to reduce local recurrence.[29] In our study, histologic grade was not predictive of metastatic potential; low-grade soft tissue sarcoma had a similar rate of metastasis as intermediate grade tumors. The high rate of metastasis in low grade soft tissue sarcoma was surprising and may reflect the large tumor size and/or the delayed time to diagnosis, or may be because of the small case cohort in our study compared to others.[30] However, the impact of a large tumor size on increased metastatic potential has been reported in human soft tissue sarcoma.[31] In our study, 8/9 chondrosarcoma were graded as intermediate which limited evaluation of this criteria on outcome.

Although chemotherapy did not appear to improve survival in patients with osteosarcoma and hemangiosarcoma in our study, case numbers were small and this apparent lack of benefit should be interpreted with caution until a larger case series is available. The apparent insensitivity of axial osteosarcoma to adjuvant chemotherapy has been reported for tumors affecting the mandible, and may suggest a different biologic behavior for osteosarcoma affecting the flat bones.[19,32]

In people, hemipelvectomy has been used for many years for the resection of neoplasms affecting the upper thigh.[33,34] Important prognostic features in people include tumor diagnosis and stage, as well as the location, size, and ability of attain a clean resection margin. Because the tumor is often occult to direct palpation and observation, difficulties similar to those we report are experienced in human patients including delays in the establishment of a definitive diagnosis, high rates of local recurrence because of local extension of tumor into adjacent pelvic structures, microscopic foci of tumor in otherwise normal tissue and widespread invasion into major pelvic veins.[34] These facets of local tumor invasion support the need for careful surgical planning to ensure resection can be accomplished without encroaching into the peritumoral environment.

Limitations of our study include the retrospective nature of the data collection, and variations in surgical technique, tumor staging, perioperative management and postoperative follow-up routines between institutions. Rates of local recurrence and metastasis may be underestimated when complete patient examination and follow up has not been consistently performed in every case. Histologic confirmation of local recurrence or metastatic disease was only available in a small number of cases with diagnosis otherwise reliant on imaging analysis or physical examination alone. Rates of metastasis may therefore be over-estimated, as there may be a tendency for a previous neoplastic event to be inappropriately blamed for the subsequent development of clinical disease in other organs (e.g., seizures, hemoabdomen). The limited numbers of patients with each tumor type will also influence subgroup analysis. For example, although tumor grade was not associated with statistically recognizable differences in patient outcome, small patient numbers and other confounding factors likely influenced this finding.

Clinical function after hemipelvectomy should be similar to that after pelvic limb amputation and will therefore be influenced by patient size, fitness, agility, and other comorbid conditions.[7] Because limb sacrifice is often required with hemipelvectomy, case selection for surgery is similar to pelvic limb amputation. Recognition of co-morbidities such as neurologic or orthopedic disease affecting other limbs is essential in the surgical planning phase; obesity and large breed

size may also make a patient unsuitable for surgery. Two dogs in our study failed to adjust well to their amputee status despite not having any obvious physical rationale for their incapacity. Four other animals experienced deterioration in mobility because of development of orthopedic disease in their remaining limbs; in these cases the erosion of quality of life and limited treatment options ultimately led to their early euthanasia despite adequate tumor control. Thus, owners need to be aware that whilst hemipelvectomy may provide an effective strategy for tumor management, adaptation by the patient in the long term cannot always be consistently assured.

Our results suggest that dogs and cats undergoing hemipelvectomy can adapt and return to acceptable clinical activity quickly and with few major complications. It cannot be overstated that surgery requires good anatomic knowledge of the pelvic region. Hemipelvectomy is a major surgical procedure with potential for major hemorrhage because of transection through large muscle groups and proximity to large vessels. Hemorrhage requiring transfusion or aggressive volume support may arise despite anatomic knowledge and sound surgical technique. Nevertheless, when performed with care and good anesthesia support, hemipelvectomy does not appear to be associated with a high degree of intraoperative or postoperative morbidity. Coaxial imaging is considered essential to assist with surgical planning. STs for most tumor types can be good, but careful evaluation of surgical margins should be performed to improve detection of incomplete tumor margins. Importantly, high rates of local recurrence and distant metastases were observed for some tumor types. Although local recurrence rates may be improved by better case selection and an improved understanding of the surgical technique, a precise role for adjuvant chemotherapy for all tumor types cannot be concluded from this study. Continued extrapolation from other studies of similar tumors at other anatomic sites will be necessary until a larger case series is available.

REFERENCES

1. Straw RC, Withrow SJ, Powers BE: Partial or total hemipelvectomy in the management of sarcomas in nine dogs and two cats. *Vet Surg* 1992;21:183–188
2. Alexander J, Carb A: Subtotal hemipelvectomy in the dog. *J Vet Orthop* 1979;1:9–14
3. Kasa G, Kasa F: Partial hemipelvectomy in the cat and dog. *Prakt Tierarzt* 1986;67:498–499
4. Kramer A, Walsh PJ, Seguin B: Hemipelvectomy in dogs and cats: technique overview, variations, and description. *Vet Surg* 2008;37:413–419
5. Kirpensteijn J, van den Bos R, Endenburg N: Adaptation of dogs to the amputation of a limb and their owners' satisfaction with the procedure. *Vet Rec* 1999;144:115–118
6. Dennis MM, McSporran KD, Bacon NJ, et al: Prognostic factors for cutaneous and subcutaneous soft tissue sarcomas in dogs. *Vet Pathol* 2011;48:73–84
7. Kirpensteijn J, Kik M, Rutteman GR, et al: Prognostic significance of a new histologic grading system for canine osteosarcoma. *Vet Pathol* 2002;39:240–246
8. Lamont LA: Adjunctive analgesic therapy in veterinary medicine. *Vet Clin North Am Small Anim Pract* 2008;38:1187–1203
9. Bray J: Hemipelvectomy: a revised surgical technique and clinical experiences from a large retrospective study. *Vet Surg* 2013
10. Waltman SS, Seguin B, Cooper BJ, et al: Clinical outcome of nonnasal chondrosarcoma in dogs: thirty-one cases (1986–2003). *Vet Surg* 2007;36:266–271
11. McSporran KD: Histologic grade predicts recurrence for marginally excised canine subcutaneous soft tissue sarcomas. *Vet Pathol* 2009;46:928–933
12. Doddy FD, Glickman LT, Glickman NW, et al: Feline fibrosarcomas at vaccination sites and non-vaccination sites. *J Comp Pathol* 1996;114:165–174
13. Enneking WF, Spanier SS, Goodman MA: A system for the surgical staging of musculoskeletal sarcoma. *Clin Orthop Relat Res* 1980; 106–120
14. Liptak JM, Kamstock DA, Dernell WS, et al: Oncologic outcome after curative-intent treatment in 39 dogs with primary chest wall tumors (1992–2005). *Vet Surg* 2008;37:488–496
15. Boston S: editor. Clinical outcome of 42 dogs with scapular bone tumors treated by scapulectomy: A VSSO Retrospective Study (1995–2010). *1st Scientific Meeting of the Veterinary Society of Surgical Oncology (VSSO);* 2012; Fort Collins, CO, USA
16. Dickerson ME, Page RL, LaDue TA, et al: Retrospective analysis of axial skeleton osteosarcoma in 22 large-breed dogs. *J Vet Intern Med* 2001;15:120–124
17. Pirkey-Ehrhart N, Withrow SJ, Straw RC, et al: Primary rib tumors in 54 dogs. *J Am Anim Hosp Assoc* 1995;31:65–69
18. Straw RC, Powers BE, Klausner J, et al: Canine mandibular osteosarcoma: 51 cases (1980–1992). *J Am Anim Hosp Assoc* 1996;32:257–262
19. Coyle VJ, Rassnick KM, Borst LB, et al: Biological behaviour of canine mandibular osteosarcoma. A retrospective study of 50 cases (1999–2007). *Vet Comp Oncol* 2013; doi: 10.1111/vco.12020
20. Kruse MA, Holmes ES, Balko JA, et al: Evaluation of clinical and histopathologic prognostic factors for survival in canine osteosarcoma of the extracranial flat and irregular bones. *Vet Pathol* 2012;50:704–708
21. Shaw SC, Kent MS, Gordon IK, et al: Temporal changes in characteristics of injection-site sarcomas in cats: 392 cases (1990–2006). *J Am Vet Med Assoc* 2009;234:376–380
22. Morrison WB, Starr RM: Vaccine-associated feline sarcomas. *J Am Vet Med Assoc* 2001;218:697–702
23. Ehrhart N: Soft-tissue sarcomas in dogs: a review. *J Am Anim Hosp Assoc* 2005;41:241–246
24. Ettinger SN: Principles of treatment for soft-tissue sarcomas in the dog. *Clin Tech Small Anim Pract* 2003;18:118–122
25. Coomer A, Farese J, Milner R, et al: Radiation therapy for canine appendicular osteosarcoma. *Vet Comp Oncol* 2009;7:15–27
26. Kamstock DA, Ehrhart EJ, Getzy DM, et al: Recommended guidelines for submission, trimming, margin evaluation, and reporting of tumor biopsy specimens in veterinary surgical pathology. *Vet Pathol* 2011;48:19–31
27. D'Adamo DR: Appraising the current role of chemotherapy for the treatment of sarcoma. *Semin Oncol* 2011;38(Suppl3):S19–S29

28. Selting KA, Powers BE, Thompson LJ, et al: Outcome of dogs with high-grade soft tissue sarcomas treated with and without adjuvant doxorubicin chemotherapy: 39 cases (1996–2004). *J Am Vet Med Assoc* 2005;227:1442–1448
29. Elmslie RE, Glawe P, Dow SW: Metronomic therapy with cyclophosphamide and piroxicam effectively delays tumor recurrence in dogs with incompletely resected soft tissue sarcomas. *J Vet Internal Med* 2008;22: 1373–1379
30. Kuntz CA, Dernell WS, Powers BE, et al: Prognostic factors for surgical treatment of soft-tissue sarcomas in dogs: 75 cases (1986–1996). *J Am Vet Med Assoc* 1997;211: 1147–1151
31. Pervaiz N, Colterjohn N, Farrokhyar F, et al: A systematic meta-analysis of randomized controlled trials of adjuvant chemotherapy for localized resectable soft-tissue sarcoma. *Cancer* 2008;113:573–581
32. Kosovsky JK, Matthiesen DT, Marretta SM, et al: Results of partial mandibulectomy for the treatment of oral tumors in 142 dogs. *Vet Surg* 1991;20:397–401
33. Beck LA, Einertson MJ, Winemiller MH, et al: Functional outcomes and quality of life after tumor-related hemipelvectomy. *Phys Ther* 2008;88:916–927
34. Wedemeyer C, Kauther MD: Hemipelvectomy—only a salvage therapy? *Orthop Rev (Pavia)* 2011;3:e4