# Lateral Caudal Axial Pattern Flap in 13 Dogs

Vincenzo Montinaro[1], DVM, Federico Massari[1], DVM, DECVS, Luca Vezzoni[1], DVM, Julius M. Liptak[2], BVSc, MVetClinStud, FACVSc, DACVS, DECVS, Rod C. Straw[3], BVSc DACVS, Larie Allen[4], DVM DACVS, Ryan P. Cavanaugh[5], DVM DACVS, John Berg[6], DVM DACVS, Ronan S. Doyle[7], MRCVS, DECVS, Paolo Buracco[8], DVM, DECVS, and Giorgio Romanelli[1], DVM, DECVS

[1] Clinica Veterinaria Nerviano, Milan, Italy ,[2] Alta Vista Animal Hospital, Ottawa, Ontario, Canada ,[3] The Australian Animal Cancer Foundation, Brisbane Veterinary Specialist Centre, Brisbane, Australia ,[4] Wheat Ridge Veterinary Specialists, Wheat Ridge, Colorado ,[5] Specialized Veterinary Services, Fort Myers, Florida ,[6] Department of Clinical Sciences, Cummings School of Veterinary Medicine, Tuft University, North Grafton, Massachusetts ,[7] Davies Veterinary Specialists, Hertfordshire, UK and [8] Department of Animal Science, University of Turin, Turin, Italy

**Corresponding Author**
V. Montinaro, DVM, Clinica Veterinaria Nerviano, Via Lampugnani 3, 20014 Nerviano, Milan, Italy.
E-mail: vm@cvnsrl.it

Submitted March 2014
Accepted September 2014

DOI:10.1111/j.1532-950X.2014.12305.x

**Objective:** To describe the frequency and extent of complications associated with lateral caudal axial pattern flaps used to cover large traumatic or excision skin defects on the dorsum, gluteal, and perineal region in 13 dogs.
**Study Design:** Case series.
**Animals:** Thirteen client-owned dogs.
**Methods:** Medical records from 8 institutions were reviewed for dogs treated with a lateral caudal axial pattern flap, including cases in which the procedure was combined with other reconstructive techniques. The flap length relative to the tail length, location of tail skin incision, size and cause of the defect, and short- and long-term complications were recorded.
**Results:** Thirteen dogs were included, 11 with tumors and 2 with traumatic skin loss. The mean estimated length of the flap relative to tail length was 51% (range 33–70%). Four dogs had wound complications. This included 2 dogs with minor postoperative wound complications (mild distal dehiscence) that did not require surgical revision and 2 dogs with major complications that required surgical revision. Two of these 4 dogs had distal flap necrosis, one was revised surgically and one was managed conservatively. In these 2 dogs, the flap length was estimated as 80% and 65% of the tail length, respectively. At 30 days, flaps in all dogs were completely healed. No long-term complications were recorded in any dog. For some dogs, the reconstruction was not obvious, with only the change in hair direction and color noticeable.
**Conclusion:** Lateral caudal axial pattern flap is a reconstructive option for gluteal, dorsal, and perineal skin defects in dogs. Distal flap necrosis and dehiscence due to wound infection occurred in 4 dogs that required additional wound care but not always surgical revision.

Surgical reconstruction of large skin defects of the gluteal, perineum, and tail base can be challenging.[1] Reconstruction can be accomplished by subdermal (local) plexus flaps, full thickness skin grafts, axial pattern flaps, or a combination of procedures.[2] Second-intention healing is less than ideal due to tail movement and the healing time can be prolonged.[1–3] Local flaps depend on the subdermal plexus vascularity for survival and may undergo necrosis if ideal length to width ratios are exceeded.[4] Axial pattern flaps are local skin flaps incorporating a direct cutaneous artery and vein,[5] which facilitates the transposition of a relatively large section of skin in a single stage procedure.[6] Axial pattern flaps are reported to have a flap viability rate 87–100%.[6–9]

The lateral caudal axial pattern flap requires sacrifice of the bony structures of the tail and has been reported in 2 cases and in an experimental study.[1,2,10] The aim of this report is to describe the frequency and extent of complications, and outcome, in 13 dogs with skin defects reconstructed with a lateral caudal axial pattern flap.

## MATERIALS AND METHODS

This study was initiated as an informal request to the Veterinary Society of Surgical Oncology (VSSO) list serve for dogs treated with the lateral caudal axial pattern flap from 2005 to 2012. The flaps were used to reconstruct large traumatic or excision skin defects of the dorsum, gluteal, and perineal region.

Medical records of dogs from contributing institutions were retrospectively reviewed. Data retrieved included age, breed, sex, weight, results of preoperative diagnostic evaluation, the cause of the skin defect (tumor excision or trauma), and approximate size of the skin defect. The location

 

of the skin incision on the tail (dorsal vs. ventral) for flap preparation, any short- (≤15 postoperative days) and long-term (>15 postoperative days) complications, and histologic diagnosis with surgical margins evaluation was also recorded. Complications were categorized as minor when they were managed conservatively and major when surgical intervention was required. Contributors were also asked to subjectively estimate the flap length as a percentage of the tail length. Histologic diagnosis was based on the original assessment of the attending pathologist at the time of specimen submission. The adequacy of tumor excision was based on histologic determination of surgical margins. Surgical margins were defined as R0 (no microscopic disease at the resection margins), R1 (no microscopic disease at the resection margin but minimal distance between tumor and resection margin), and R2 (microscopic disease at tumor margin).[11]

## RESULTS

### *Signalment*

Information from 13 dogs including Labrador Retrievers (n = 2), mixed-breed breeds (2) and 1 each of English Setter, Akita, Entlebucher Mountain Dog, Staffordshire Bull Terrier, Australian Cattle Dog, Cane Corso, Rhodesian Ridgeback, Siberian Husky, and Brie Shepherd Dog was used (Table 1). Mean body weight was 31 kg (range 13–51 kg). Mean age at presentation was 8 years (range 4–16 years). There were 9 males (6 intact, 3 neutered) and 4 females (1 intact, 3 neutered).

### *Presenting Complaint*

The skin defect was the result of tumor resection (n = 11) and trauma (2) (Table 1). Tumors resected included soft tissue sarcoma (n = 5), mast cell tumor (2), hepatoid gland carcinoma (2), squamous cell carcinoma (1), and infected perineal adenoma (1). All excisions were complete based on histologic margin assessment, categorized as R0 in 10 dogs and R1 in 1 dog.

One dog was missing for 3 days and sustained unknown trauma. The dog had flaccid tail paralysis, sacrococcygeal luxation, and a large open wound with major soft tissue loss (skin, subcutaneous tissue, and a portion of superficial gluteal muscle) over the left gluteal region. The wound was managed with a wet-to-dry bandage for 14 days prior to reconstruction. A second dog presented with a degloving injury of the right perineum and caudal dorsum, with concurrent rectal perforation, all secondary to a dog fight. The rectum was debrided and sutured. The perineal wound was managed as an open wound until healthy granulation tissue was present, then reconstructed.

### *Preoperative Diagnostic Tests*

Preoperative cytologic examination after fine needle aspiration in 4 dogs reported mast cell tumors (n = 2), hepatoid adenocarcinoma (1), and perianal adenoma with secondary infection (1). Preoperative cytologic examination was performed in an additional 3 dogs that had previous tumor resection at the same location. Cytologic examination confirmed the recurrence of soft tissue sarcoma (n = 2) and squamous cell carcinoma (1). Histologic examination of incisional biopsies in 4 dogs reported soft tissue sarcoma.

Preoperative imaging for clinical staging included 3-view thoracic radiographs (n = 10) and abdominal ultrasound.[9] Thoracic radiographs were within normal limits in all dogs examined. Thoracic radiographs were not performed in 2 dogs with traumatic wounds and 1 dog with an infected perianal adenoma. Abdominal ultrasound was normal in all dogs

**Table 1** Clinical Features of 13 Dogs Undergoing Wound Reconstruction With a Lateral Caudal Axial Pattern Flap

| Dog | Defect origin | Tail incision | Defect size (cm) | Flap length (% tail length) | Short-term complication (≤15 days) |
|---|---|---|---|---|---|
| English Setter | Mast cell tumor grade 2; perineal area | Ventral | 20 × 20 | 33 | None |
| Labrador Retriever | Mast cell tumor grade 2; tail base | Dorsal | 12 × 12 | 33 | None |
| Akita* | Trauma; tail base | Dorsolateral | 13 × 8 | 40 | None |
| Entlebucher Mountain Dog | Squamous cell carcinoma; tail base | Dorsal | 15 × 15 | 50 | None |
| Staffordshire Bull Terrier | Soft tissue sarcoma grade 2 recurrence; tail base | Dorsal | 15 × 9 | 40 | Wound dehiscence; surgical revision |
| Labrador Retriever | FSA G3; left hip region | Dorsolateral | 15 × 13 | 50 | Mild dehiscence; conservative |
| Australian Cattle Dog | Trauma; caudal dorsum and right perineal region | Dorsolateral | 12 × 8 | 80 | Mild distal flap necrosis; surgical revision |
| Cane Corso | Infected perianal adenoma; perineal area | Ventral | 7 × 7 | 70** | None |
| Mixed breed | Fibrosarcoma; dorsum, from ilium to base of the tail | Dorsal | 20 × 20 | 55 | None |
| Mixed breed | Hepatoid adenocarcinoma; perineum | Ventral | 7 × 7 | 40 | None |
| Rhodesian Ridgeback | Peripheral nerve sheath tumor; ischium | Dorsolateral | 15 × 15 | 65 | Mild distal flap necrosis; conservative |
| Siberian Husky | Peripheral nerve sheath tumor; ischium | Dorsolateral | 12 × 12 | 47 | None |
| Brie Shepherd dog | Hepatoid adenocarcinoma gluteal region | Ventrolateral | 13 × 13 | 40 | None |

*Dog with 1 lateral caudal vessel only.
**Dog with docked tail.

examined. Computed tomography of the pelvic region was performed for surgical planning in 3 dogs.

**Lateral Caudal Axial Pattern Flap.** Dogs were anesthetized and positioned in sternal recumbency. The tail, caudodorsal, and caudolateral areas of the body were clipped and prepared for aseptic surgery depending on the location of the lesion. In general, starting from the tail base along its entire length, a sagittal dorsal or ventral tail incision was performed depending on the location of the skin defect to be covered. A ventral incision was used when the defect was in the caudoventral perineal region and a dorsal incision when the defect was located in the caudodorsal and dorsal gluteal region. To ensure adequate margins for some tumor excisions, a dorsolateral or ventrolateral skin incision was used. A dorsolateral incision was used in 5 dogs, dorsal in 4, ventral in 3, and ventrolateral in 1. Lateral coccygeal arteries and veins were meticulously preserved during flap isolation by dissecting as close as possible to the coccygeal vertebrae. The tail was usually amputated between the second and third coccygeal vertebra. The mean length of the flap, estimated as a percentage of the tail length was 51% (range 33–70%). One dog had a docked tail. In this dog the entire tail was used and it was estimated subjectively by the surgeon as being 70% of the normal length for the dog prior to docking. The flap was rotated and positioned over the skin defect with excess length trimmed as needed. In 1 dog, the lateral caudal flap was not wide enough to cover the whole skin defect and was combined with a caudal superficial epigastric axial pattern flap. The lateral caudal flap was first positioned dorsally and then the caudal superficial epigastric flap was rotated 90° to reconstruct the ventrolateral aspect of the defect. In another dog, the cranial two-thirds of the defect was reconstructed with an inguinal flank fold flap and the caudal third with the lateral caudal flap. A partial sagittal ostectomy of the ischium (Fig 1) and ilium was performed in 2 dogs to achieve deep surgical margins. In 1 dog, the left coccygeal artery and vein appeared to be damaged by previous trauma; however, the right coccygeal artery and vein provided sufficient vascularization to the entire tail skin, evident by the successful outcome. An active suction drain was placed in 8 dogs, a Penrose drain in 1 dog, and no drain in 4 dogs. The subcutaneous tissue and skin of the flap were sutured (Fig 2). Dogs were discharged (2–7 days postoperative), which was after drain removal in 9 dogs. Flaps were evaluated for viability at the time of discharge, suture removal (approximately 10 days postoperative), and during routine recheck examinations (mean 79 days, range 30–365 days).

### *Surgical Outcome*

Short-term postoperative (≤15 days) complications were recorded in 4 dogs (30%). Two dogs (15%) had minor postoperative wound complications at the tip of the flap with mild dehiscence (4 cm) in 1 dog and 2 $cm^2$ distal flap necrosis in 1 dog. No surgical revision was required in either dog. The first dog was managed with culture-specific antibiotic therapy (enrofloxacin 5 mg PO once daily and metronidazole 10 mg PO twice daily) for a *Pseudomonas aeruginosa* and *Bacteroides fragilis* infection. A tie-over bandage was applied. The second dog received surface debridement. Both dogs had resolution with second intention healing.

Two dogs had major postoperative wound complications requiring surgical revision. Distal flap necrosis occurred in 1 dog with a traumatic wound and rectal perforation. The flap was debrided and primary closure was performed. Major wound dehiscence in the second dog was initially managed as an open wound with wet-to-dry bandages for 14 days prior to surgical revision and definitive closure.

No dog had long-term (>15 days) complications. At 30 days, all flaps had healed and the only obvious change was the different direction and color of the hair coat, noticeable in dogs undergoing a dorsal tail skin incision (Fig 3).

## DISCUSSION

This case series describes the successful use of the lateral caudal axial pattern flap for reconstruction of large defects of the dorsum, gluteal, and perineal area in dogs. Axial pattern flaps include a direct cutaneous artery and vein with the flap area determined by the angiosome of the direct cutaneous artery. The direct cutaneous blood supply allows for the transposition of an extensive area of skin in a single procedure.[12] Axial pattern flaps suitable for closure of caudodorsal skin defects include the dorsal deep circumflex iliac and caudal superficial epigastric axial pattern flaps.[12,13] However, these flaps may not be suitable for reconstruction of some dorsal skin defects that go beyond the arc of rotation of these flaps or exceed the defined limit of the flaps, increasing the risk of distal flap necrosis.[2]

A previous experimental study[2] and 2 case reports[1,10] showed the lateral caudal axial pattern flap based on the lateral coccygeal artery is a suitable option for coverage of large gluteal, perineal, and dorsal cutaneous wounds, either as a single axial pattern flap or combined with other reconstructive procedures. The vascular supply of the tail originates from the medial sacral artery, which continues as median caudal artery and caudal gluteal arteries that give rise to the lateral caudal arteries.[14] The lateral caudal arteries and veins course the length of the tail in a left and right lateral location, ventral to transverse processes of the caudal vertebrae proximally and then dorsal to the transverse processes distally (Fig 4).[1] Tail amputation causes loss of the cutaneous contribution of the medial caudal artery, but meticulous dissection of the deep caudal fascia preserves direct cutaneous arterial supply from the lateral caudal arteries. This long, narrow axial pattern flap has the advantage of being vascularized by 2 direct cutaneous arteries.[1] In 1 dog of this series, the flap was based on a single lateral coccygeal artery and vein as the contralateral vessel had been traumatized. This flap survived without any wound complication, which suggests diffuse vascularity from vessels on both sides. The flap was constructed using only 40% of the original length of the tail, which may have facilitated survival. In 2 dogs, the lateral caudal axial pattern flap was not large enough to cover the defect and an inguinal fold skin flap or

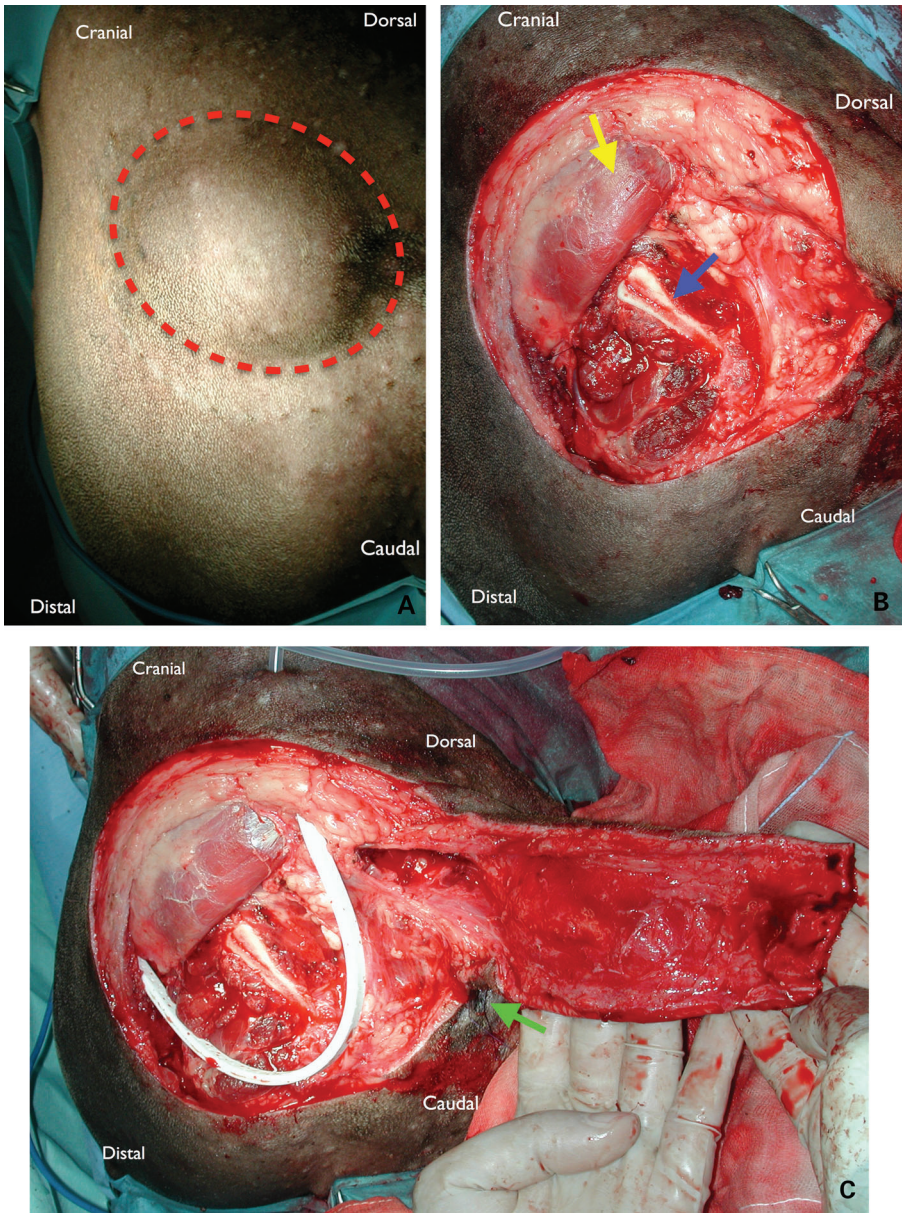


**Figure 1** (A) Preoperative appearance of a soft tissue sarcoma (dotted line) located cranial to the ischiatic tuberosity in a 10-year-old Rhodesian Ridgeback. (B) Intraoperative appearance after tumor excision and ostectomy of the ischiatic tuberosity. Blue arrow indicates the ischium. Yellow arrow indicates the superficial gluteal muscle. (C) Intraoperative positioning of the Jackson-Pratt closed suction drain, anal purse-string suture (green arrow) and the extension of the lateral cadual axial pattern flap before being sutured to close the defect.

caudal superficial epigastric axial pattern flap were also required for reconstruction of the defect.

Complications observed in this case series include necrosis of the distal aspect of the flap, dehiscence, and infection. Distal flap necrosis occurred in 2 dogs, one managed conservatively and one managed by surgical revision. The flaps were estimated 65% and 80% of the tail length. Increasing the flap length may result in loss of distal perfusion and subsequent necrosis.[15–18] It has been recommended that the maximum length of the lateral caudal axial pattern flap should not exceed 78% of the tail length to minimize the risk of distal flap necrosis.[2] These authors reported a mean failure of 22% of the total flap area.[2] We would recommend caution using the lateral caudal axial pattern flap beyond 60% of the tail length to minimize the risk of distal flap necrosis although one dog in our series had no complications despite a flap estimated as 70% of the tail length.

Postoperative seroma formation is reported as a complication following reconstruction with axial pattern flaps.[6,13] We did not report seroma but this may have been because drains

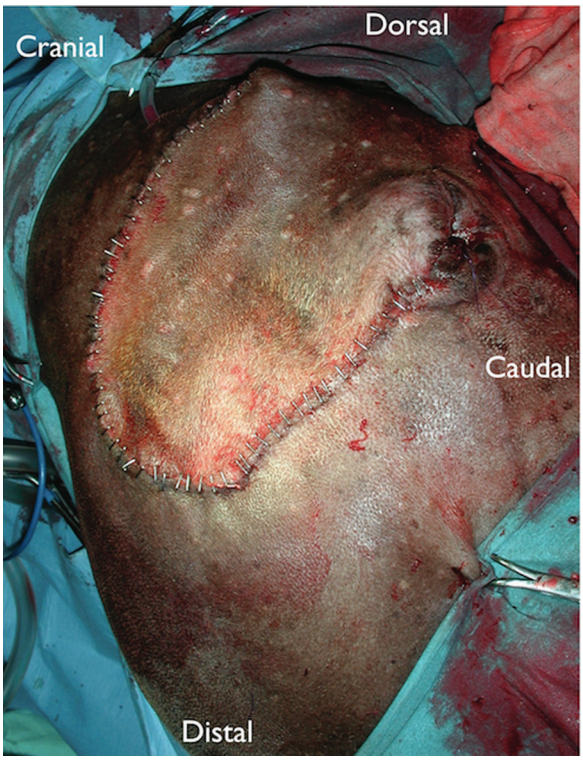


**Figure 2** Immediate postoperative appearance after transposition of a lateral caudal axial pattern flap after excision of a soft tissue sarcoma in a 10-year-old Rhodesian Ridgeback (shown in Fig 1).

were used in most dogs and because the flaps were relatively short. The use of soft, padded, tie-over bandage to obliterate dead space and avoid self-mutilation has been reported as an alternative to drain placement to avoid seroma formation.[2]

**Figure 3** Appearance of a lateral caudal axial pattern flap 45 days after transposition in a 10-year-old Rhodesian Ridgeback (shown in Figs 1 and 2). Note the different hair direction of the flap.

**Figure 4** Radiographs of tail vascularization in a normal dog after intravenous contrast injection. Note the lateral coccygeal arteries.

This study has limitations because it is retrospective and multi-institutional, which prohibits a standardized evaluation and treatment protocol. A small number of dogs were enrolled but this reflects the very specific nature of the application of this flap. The estimate of flap length as a percentage of tail used could only be based on retrospective, subjective assessment by each contributor. The cases were collated after an informal request to the Veterinary Society of Surgical Oncology

(VSSO) list serve. This relies on self reporting and may bias the estimation regarding success, flap survival, and complications because clinicians usually prefer to report only successful cases and they may fear being judged by their peers. All these elements may have resulted in bias in reporting the results.

This study shows that the lateral caudal axial pattern flap based on the lateral coccygeal artery, alone or combined with other regional flaps, offers a reliable reconstructive option for skin defects in the gluteal, perineal, and dorsal regions of the dog after wide tumor excision or traumatic skin loss.

## REFERENCES


1. Smith MM, Carrig CB, Waldron DR, et al: Direct cutaneous arterial supply to the tail in dogs. *Am J Vet Res* 1992;53:145–148
2. Saifzadeh S, Hobbenaghi R, Noorabadi M: Axial pattern flap based on the lateral caudal arteries of the tail in the dog: an experimental study. *Vet Surg* 2005;34:509–513
3. Stanley BJ, Pitt KA, Weder CD, et al: Effect of negative pressure wound therapy on healing of free full-thickness skin graft in dogs. *Vet Surg* 2013;42:511–522
4. Hunt GB: Local or subdermal plexus flap, in Tobias KM, Johnston SA (eds): *Veterinary surgery small animal* (vol 2). St. Louis, MO: Elsevier Saunders, 2012, pp 1243–1255
5. Wardlaw JL, Lanz OI: Axial pattern and myocutaneous flaps, in Tobias KM, Johnston SA (eds): *Veterinary surgery small animal* (vol 2). St. Louis, MO: Elsevier Saunders, 2012, pp 1256–1270
6. Aper R, Smeak D: Complications and outcome after thoracodorsal axial pattern flap reconstruction of forelimb skin defects in 10 dogs, 1989–2001. *Vet Surg* 2003;32:378–384
7. Trevor PB, Smith MM, Waldron DR, et al: Clinical evaluation of axial pattern skin flaps for wound closure in dogs and cats: 19 cases (1981–1990). *J Am Vet Med Assoc* 1992;201:608–612
8. Aper RL, Smeak DD: Clinical evaluation of caudal superficial epigastric axial pattern flap reconstruction of skin defects in 10 dogs (1989–2001). *J Am Anim Hosp Assoc* 2005;41:185–192
9. Remedios AM, Bauer MS, Bowen CV: Thoracodorsal and caudal superficial epigastric axial pattern skin flaps in cats. *Vet Surg* 1989;18:380–385
10. Cawey AJ, Archibald J: Plastic surgery, in Archibald J (ed): *Canine surgery.* Santa Barbara, CA, American Veterinary Publication, 1974, pp 136–139
11. Wittekind C, Compton C, Quirke P, et al: A uniform residual tumor (R) classification. *Cancer* 2009;115:3483–3488
12. Pavletic MM: Canine axial pattern flaps, using the omocervical, thoracodorsal and deep circumflex iliac direct cutaneous arteries. *Am J Vet Res* 1981;42:391–406
13. Pavletic MM: Axial pattern skin flaps, in Pavletic MM (ed): *Atlas of small animal wound management and reconstructive surgery* (ed 3). St. Louis, MO: WB Saunders, 2010, pp 400–401
14. Evans HE: The heart and arteries, in Miller ME, Evans HE (eds): *Anatomy of the dog*. St. Louis, MO: WB Saunders, 1993, pp 678–679
15. Pavletic MM: Caudal superficial epigastric arterial pedicle grafts in the dog. *Vet Surg* 1980;9:103–107
16. Spodnick GJ, Hudson LC, Clark GN, et al: Use of a caudal auricular axial pattern flap in cats. *J Am Vet Med Assoc* 1996;208:1679–1682
17. Smith MM, Payne JT, Moon ML, et al: Axial pattern flap based on the caudal auricular artery in dogs. *Am J Vet Res* 1991;52:922–925
18. Sardinas JC, Paveltic MM, Ross T, et al: Comparative viability of peninsular and island axial pattern flap flaps incorporating the cranial superficial epigastric artery in dogs. *J Am Vet Med Assoc* 1995;207:452–454